



## The Use of the Thoracodorsal Artery Perforator Flap in Both Autologous and Implant Based Breast Reconstruction Salvage Surgery

Nizamoglu M<sup>1\*</sup>, Hardwick S<sup>1</sup>, Coulson S<sup>1</sup> and Malata CM<sup>1,2,3</sup>

<sup>1</sup>Department of Plastic and Reconstructive Surgery, Addenbrooke's Hospital, Cambridge University Hospitals NHS Foundation Trust, UK

<sup>2</sup>Cambridge Breast Unit, Addenbrooke's Hospital, Cambridge University Hospitals NHS Foundation Trust, UK

<sup>3</sup>Anglia Ruskin University School of Medicine, UK

### Abstract

**Introduction:** Since its introduction by Angrigiani the Thoracodorsal Artery Perforator (TDAP) flap has become a popular choice in partial breast reconstruction for volume replacement. Although mainly used to provide volume, it has also been reported as an adjunct to implant-based breast reconstruction.

**Methods:** Patients undergoing salvage breast reconstruction surgery with the TDAP flap in the last 20 years were identified from the senior author's logbook and their clinical data collected from EpicTM, the hospital electronic medical records system.

**Results:** Two such patients, aged 44 and 52 years, were identified. The first had "impending failure" of a subpectoral implant reconstruction following severe cutaneous radiation reaction and poor quality soft tissues overlying the implant, coupled with recurrent seromas. The second had partial SIEA abdominal free flap fat necrosis, leading to volume loss, severe cutaneous scarring and significant deformity. The flap dimensions were 10 cm × 25 cm and 8 cm × 25 cm, respectively. They were each based on a single vascular perforator— one arising from the horizontal and the other from the vertical branch of the thoracodorsal vessels. Both flap transfers were successful and resulted in viable reconstructions despite the challenging indications.

**Discussion and Conclusion:** The TDAP flap was successfully used to perform salvage breast reconstruction in both prosthetic and autologous cases which presented with ongoing challenges. We believe our technique of the TDAP flap for tertiary breast reconstruction provides adequate soft tissue replacement with minimal donor morbidity, and advocate that it be considered for difficult salvage cases when other options are not available.

**Keywords:** TDAP flap; Perforator flap; SIEA flap; Fat necrosis; Impending implant exposure; Recurrent seromas; Partial breast reconstruction; Oncoplastic surgery; Salvage breast reconstruction

### Introduction

The Thoracodorsal Artery Perforator (TDAP) flap is a fasciocutaneous perforator flap based on the thoracodorsal vessels [1]. It allows autologous pedicled vascularized tissue coverage whilst avoiding the morbidity of Latissimus Dorsi (LD) myocutaneous flap harvest. This highly versatile flap has become a popular choice for partial breast reconstruction for volume replacement usually in the immediate reconstructive setting. It is most commonly used in (immediate) partial breast reconstruction [2-4]. It can be islanded [5] or employed as a peninsular flap [6]. Its use has extended to partial breast reconstruction in the delayed setting, i.e., correction of lumpectomy deformities. However, it has also found application in total post-mastectomy immediate and delayed breast reconstruction as an adjunct to implants/expanders [7-11]. More recently it has also been employed as a cheaper substitute for Acellular Dermal Matrix (ADM) in immediate implant-based breast reconstruction [12]. The key application of the TDAP flap in the context of breast reconstruction is in recruiting soft, supple skin and adding volume. To this end, it can counteract the effects of radiotherapy in patients with severe radiation-induced changes. Similarly, patients with flap vascularity problems can present with late skin and soft tissue deformities which require autologous

### OPEN ACCESS

#### \*Correspondence:

Metin Nizamoglu, Department of Plastic and Reconstructive Surgery, Addenbrooke's Hospital, Box 186, Cambridge University Hospitals NHS Foundation Trust, Hills Road, Cambridge, CB2 2QQ, UK, E-mail: mnizam@doctors.org.uk

Received Date: 26 Oct 2020

Accepted Date: 24 Nov 2020

Published Date: 28 Nov 2020

#### Citation:

Nizamoglu M, Hardwick S, Coulson S, Malata CM. The Use of the Thoracodorsal Artery Perforator Flap in Both Autologous and Implant Based Breast Reconstruction Salvage Surgery. Clin Surg. 2020; 5: 3006.

**Copyright** © 2020 Nizamoglu M. This is an open access article distributed under the Creative Commons Attribution License, which permits unrestricted use, distribution, and reproduction in any medium, provided the original work is properly cited.

tissue salvage. We, therefore, reviewed two cases of TDAP flap use in salvage breast reconstruction by the senior author in the last 20 years. The aim was to highlight its versatility in addressing challenging salvage situations for both autogenous and prosthetic breast reconstructions and present a pragmatic overview of our technique in cases of problematic total breast reconstruction.

## Methods

### Imaging and preoperative planning

Pre-operatively a CT angiogram is performed to identify appropriate perforating vessels. This guides the decision on which branch of the TDA to raise/base the flap on and aids design of the skin paddle. The patient is placed in a lateral decubitus position with the shoulder abducted, and the elbow flexed to 90 degrees. A Doppler probe is used to mark out the selected perforator(s) on the skin paddle. An elliptical skin paddle is designed measuring up to a maximum of 10 cm × 25 cm.

### Intra-operative technique

Firstly, all non-viable and scar tissue is excised en bloc and sent for histology, leaving soft, good quality, pliable skin flaps. Subsequently, the medial, inferior and lateral extents of the pocket are redefined. The inferior skin marking of the flap is incised and deepened to muscle fascia. The dissection can be chamfered deep to Scarpa's fascia to recruit the maximum volume of fat/soft tissue. The inferolateral edge of the flap is raised, and the single dominant perforator identified. The muscle is then split and the perforator dissected cranially carefully ligating and dividing all the side branches of the perforator and the vascular pedicle. The anterior and superior part of the skin paddle is initially left attached to the LD muscle to prevent accidental avulsion of the perforator or pedicle. All side branches are liga-clipped or carefully coagulated. Care is taken to preserve the thoracodorsal nerve, which is dissected away from the pedicle. The thoracodorsal pedicle is then mobilized to its confluence with the branch to the serratus anterior, which can be divided for additional length if required; however, it is preserved if possible. Once the pedicle dissection is complete, the flap is fully released. The anterolateral edge of the LD muscle anterior to the muscle split is then elevated to allow passage of flap deep to it. The TDAP 'propeller' flap is then rotated 180 degrees and passed through a subcutaneous tunnel to reach the breast.

## Results

### Case 1

A 44-year old BRCA2 mutation-positive woman initially presented with multifocal right breast cancer which required mastectomy and radiotherapy. She also had Factor VII deficiency, which was deemed a relative contraindication to autologous free tissue transfer due to the additional risk of bleeding and microsurgical compromise. She was therefore treated with bilateral mastectomies (left prophylactic, right therapeutic with right sentinel lymph node biopsy (negative) and immediate breast reconstruction with subpectoral expanders (Becker-35™) and Surgimend® Acellular Dermal Matrix (ADM) support. She did well in the early postoperative period. However, following adjuvant radiotherapy, she developed progressive Baker grade IV capsular contracture. Therefore 16 months after the initial operation, she underwent a right capsulectomy with an exchange of the subpectoral expander to a fixed volume anatomical cohesive silicone gel implant and total implant coverage with Braxon® porcine ADM. Over the following month, she had multiple seroma collections,

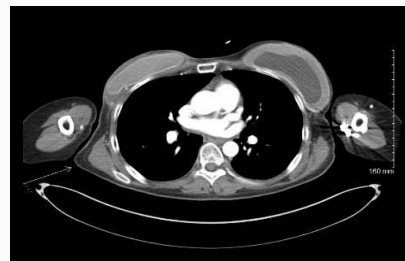


Figure 1: Case 1; Preoperative CTA showing perforators of the TDA.

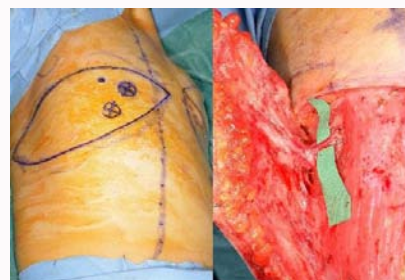

Figure 2: Case 1, Intra-operative markings.

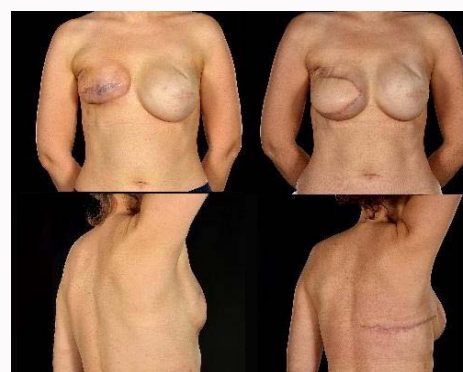

Figure 3: Case 1; Left pre-op, right post-op.

episodes of intermittent skin redness (differential diagnoses of cellulitis and "red breast syndrome") and partial wound breakdown that culminated in impending implant exposure. Therefore, she had an exchange of her right subpectoral prosthesis (totally covered with Braxon) for an expandable implant (Becker-35™). Her recovery was, however, further complicated with multiple seromas (needing aspirations) and partial wound dehiscence. The wound was debrided and peri-implant seroma washed out with direct closure two months after her implant exchange. However, this was a temporizing measure and did not adequately address the underlying issue of poor skin quality. A salvage reconstruction of the right expander-reconstructed breast with a Thoracodorsal Artery Perforator (TDAP) flap was thus performed as expander inflation was not feasible (with the thinned out poor quality skin with severe radiation changes) whilst further implants were likely to fail in the context of severe radiotherapy skin changes, underlying scarring, subclinical infection, and poor skin quality. Preoperative CT angiography of the thoracodorsal perforating vessels showed them to be adequate (Figure 1). In her case the anterior-inferior capsule and pre-existing incorporated ADM tissue were excised, but the prosthesis was deemed intact and therefore preserved. This was re-inserted after washing out the pocket with 10% aqueous povidone-iodine (betadine). The flap was raised on

a perforator from the horizontal branch of the thoracodorsal artery with a skin paddle measuring 25 cm × 10 cm (Figure 2). The patient went on to have uneventful healing with preservation of the implant and satisfactory cosmetic outcome from the TDAP flap salvage reconstruction with the resultant transverse back donor site scar easily hidden beneath the bra strap (Figure 3). The final breast mound has adequate soft tissue coverage, and any perceived (future) deficits can be corrected by further autologous fat grafting. It is additionally an excellent platform for nipple reconstruction in future.

## Case 2

A 52-year old patient with bilateral breast cancer underwent bilateral skin-reducing mastectomies with immediate bilateral free abdominal flap reconstruction. Despite previous ovarian surgery via a Pfannenstiel incision, CT angiography revealed suitable deep inferior epigastric perforator vessels. The right breast was reconstructed with a Superficial Inferior Epigastric Artery (SIEA) flap and the left using a Deep Inferior Epigastric Perforator (DIEP) flap. The right breast SIEA flap suffered partial necrosis of its inferior third managed by multiple surgical debridements and negative pressure dressings until full healing. The resulting pain, cutaneous scarring and volume deficiency were not amenable to Autologous Fat Grafting (AFG). Therefore a salvage TDAP flap was considered at 12 months after the first operation. A CT angiogram booked for preoperative planning was erroneously protocolled as a DIEP mapping scan of the abdomen (despite the previous abdominal flap harvest). Identification of suitable perforator vessels was thus performed pre- and intra-operatively with an 8-megawatt handheld Doppler. Pre-operative markings for case 2 are demonstrated in Figure 4. At surgery, the residual scarring was excised from the right breast and a “neo-breast envelope” defined and developed to accommodate the TDAP flap. The flap was based on the tortuous descending vertical branch of the TDA, and its

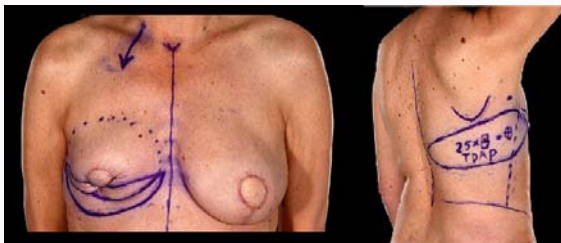


Figure 4: Case 2; pre-operative markings.

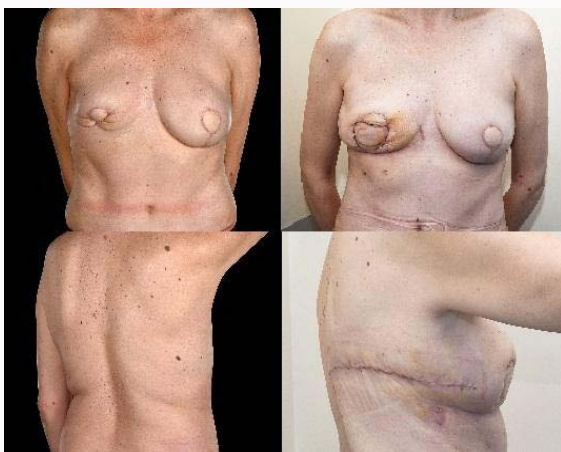


Figure 5: Case 2; Left pre-op, right post-op.

skin paddle measured 8 cm × 25 cm. The flap subsequently settled well, correcting the cutaneous deformity and volume deficit, thus providing acceptable symmetry to the patient (Figure 5).

## Discussion

The above salvage reconstruction cases were challenging for several reasons. Both patients had had 2 and 3 previous operations, respectively prior to their TDAP flap reconstruction. This resulted in both severe local scarring (made worse in the first patient by the severe radiation-induced capsular contracture), leading to significant skin contraction, asymmetry, tightness and distortion of the breast boundaries and contour. The skin quality was poor in nature, thinned out with poor vascularity, particularly in the patient treated with radiotherapy. There was a skin shortage and volume deficit that needed correcting in both cases. In the second case, the abdominal tissue had already been harvested for the initial reconstruction, requiring an alternative reconstruction method. The TDAP flap was selected in these cases as the resultant defect required 1) volume to replace the tissue debrided and 2) recruitment of non-irradiated supple skin to replace the contracted scar tissue and fill the existing skin shortage. The TDAP flap offered both skin and (limited) volume augmentation. It could, therefore, be used in isolation as an autologous partial breast reconstruction or used in conjunction with an expanded to provide robust prosthesis cover.

The TDAP flap bridged multiple surgical goals that other approaches could not otherwise have fully accomplished. Using an implant alone while addressing volume deficit would not address the contracted skin shortage and may prove disastrous in cases of wound breakdown and exposure; also an ADM was previously used in one of the patients unsuccessfully. Fat grafting alone similarly would not have been able to both augment the volume sufficiently without a multiple staged procedure and would not have addressed the skin shortages and the contour deformities. The preoperative CTA for case one showed that the LTAP flap [13] perforator was very small (after axillary clearance), therefore influencing the decision not to attempt this flap as the loco-regional option. In case two, where only an axillary sentinel lymph node biopsy had been performed, the senior author expected the LTAP flap would be available. However, in the absence of CTA confirmation, the more reliable and constant TDAP flap was selected [14]. Alternative sources of free tissue transfer could have been utilized; however these risk donor site morbidity and asymmetry, asymmetry and the vagaries of microvascular surgery in previously irradiated and scarred surgical fields, particularly in the patient with Factor VII deficiency. Furthermore, the second patient had already undergone autologous abdominal tissue harvest for their index reconstruction, and therefore this was not an option due to the non-availability of easy recipient vessels for any further microanastomosis. A notable advantage of the TDAP flap in this setting is that the pedicle is consistent [6,15,16]. There are perforating branches from both the vertical and horizontal branch of the TDA enabling different skin paddle orientations as required [17]. Additional volume can be incorporated by chamfering to include additional fat [5], and if required the muscle-sparing variations can be used; however, we did not need to sacrifice any of the muscle in our cases. By using a local pedicled option, there is a reduction in the operative time, recovery and total negation of anastomotic complications. Raising the TDAP as a fasciocutaneous flap avoids the inherent disadvantages of LD flap muscle harvest such as weakness, contour deformity, and increased risk of seromas and hematomas [18,19]. Additionally, many LD-



implant reconstruction patients subsequently require reoperation for change or removal of the prosthesis [18,20]. CTA can facilitate the procedure by providing an assessment of the location and quality of the perforating vessels, which aids surgical planning. Our experience has shown that performing a CTA pre-operatively can significantly assist the surgeon by selecting the most appropriate perforating vessel, as this will influence flap design and surgical approach used. In patient 2, the location of the optimal perforator was identified with a Doppler alone. This resulted in a lengthy dissection only to later realize a larger and more favorably coursed perforator was available, and identification of this would have been facilitated by performing CT angiogram and appropriate reporting of the exact location on the thoracic wall. We recognize surgeons can successfully perform the TDAP flap based entirely on preoperative markings made with a Doppler probe [21,22]. However, although this modality is cheaper and more easily accessible, it generates more false-positive and false-negative signals and provides less detailed anatomic and functional vessel information. The dominant TDA perforator can also be visualized by the multidetector-row computed tomographic scan, and its location is marked directly on the skin [23]. Kim et al. [24] have published a study suggesting that multiple planes of multidetector-row computed tomographic angiography may increase the probability of detecting the most reliable perforators, along with decreasing the probability of missing available vessels. We recommend performing CTA a few days prior to surgery to select the most appropriate perforator and, if possible, to align the resultant scar within the bra line for ideal aesthetic results. The TDAP flap has been well described in its use for partial breast reconstruction, but our literature search yielded only a limited number of accounts of its use in salvage cases. Banks et al. [10] described ten patients having thoracodorsal artery perforator/Muscle-Sparing Latissimus Dorsi flap breast reconstructions to enhance outcomes in implant breast reconstruction, two cases of which were for salvage. However, no detail was provided about these patients in the manuscript, although a figure illustrates that a TDAP flap was used to replace irradiated skin in one patient. Their findings indicate that in the face of previous irradiation, the TDAP flap is at least equivalent to an LD flap when used to augment implant breast reconstruction. In another article, Hamdi et al. [5] described staged salvage of sub-total flap and fat necrosis following immediate DIEP flap breast reconstruction. The first stage comprised debridement and TDAP flap reconstruction, followed by AFG and contralateral breast symmetrization. Our 2<sup>nd</sup> patient illustrates TDAP flap use to salvage fat necrosis of an SIEA flap which is more likely to happen than in the DIEP flap described by Hamdi et al. [8]. The TDAP can also provide additional volume to an implant reconstructed breast. To the author's knowledge, there has not been a series demonstrating the use of TDAP flap in the use of salvage reconstruction for both partially failed autologous and implant-based reconstruction with acellular dermal matrix breast to achieve good symmetry in a single-stage procedure. The TDAP flap is a versatile option in salvage breast reconstructive surgery, as it offers both volume for partial breast defect reconstruction and the recruitment of fresh, supple skin from outside of the zone of radiation to provide cutaneous coverage. It can be used alone or in conjunction with implant augmentation if required. Its main advantages are threefold. Firstly, it offers a large skin paddle (up to 10 cm × 25 cm). Secondly, it is a faster and safer autologous tissue reconstructive option compared to a free flap, and its reliable blood supply obviates the risks of free tissue transfer. Thirdly, the LD muscle is spared, thus lessening/diminishing donor site morbidity. Our results demonstrate

the TDAP flap can successfully be used to salvage both failed alloplastic and autologous free flap breast reconstructions if required in a single-stage procedure.

## References

- Angrigiani C, Grilli D, Siebert J. Latissimus dorsi musculocutaneous flap without muscle. *Plast Reconstr Surg*. 1995;96(7):1608-14.
- Hamdi M, Van Landuyt K, Monstrey S, Blondeel P. Pedicled perforator flaps in breast reconstruction: A new concept. *Br J Plast Surg*. 2004;57(6):531-9.
- Amin AA, Rifaat M, Farahat A, Hashem T. The role of thoracodorsal artery perforator flap in oncoplastic breast surgery. *J Egypt Natl Canc Inst*. 2017;29(2):83-7.
- Youssif S, Hassan Y, Tohamy A, Eid S, Ashour T, Malahias M, et al. Pedicled local flaps: A reliable reconstructive tool for partial breast defects. *Gland Surg*. 2019;8(5):527.
- Hamdi M, Rasheed MZ. Advances in autologous breast reconstruction with pedicled perforator flaps. *Clin Plast Surg*. 2012;39(4):477-90.
- Jash PK, Mallik M, Suba S. Pedicled thoracodorsal artery perforator flap to resurface locoregional soft tissue defects-a prospective study. *J Clin Diag Res*. 2019;13(3).
- Hamdi M, Salgarello M, Barone-Adesi L, Van Landuyt K. Use of the Thoracodorsal Artery Perforator (TDAP) flap with implant in breast reconstruction. *Ann Plast Surg*. 2008;61(2):143-6.
- Adler N, Seitz IA, Song DH. Pedicled thoracodorsal artery perforator flap in breast reconstruction: Clinical experience. *Eplasty*. 2009;9.
- Angrigiani C, Rancati A, Escudero E, Artero G, Gercovich G, Deza EG. Propeller thoracodorsal artery perforator flap for breast reconstruction. *Gland Surg*. 2014;3(3):174.
- Bank J, Ledbetter K, Song DH. Use of thoracodorsal artery perforator flaps to enhance outcomes in alloplastic breast reconstruction. *Plast Reconstr Surg Global Open*. 2014;2(5).
- di Pompeo FS, Sorotos M. Total breast reconstruction using the thoracodorsal artery perforator flap TDAP. *Breast Reconstruction*. 2020;137-45.
- Hashem T, Farahat A. Thoracodorsal artery perforator flap as an autologous alternative to acellular dermal matrix. *World J Surg Oncol*. 2017;15(1):185.
- McCulley SJ, Schaverien MV, Tan VK, Macmillan RD. Lateral Thoracic Artery Perforator (LTAP) flap in partial breast reconstruction. *J Plast Reconstr Aesthet Surg*. 2015;68(5):686-91.
- Florczak A-S, Chaput B, Herlin C, Rousseau P, Watier E, Bertheuil N. The use of pedicled perforator flaps in chest reconstruction: A systematic review of outcomes and reliability. *Ann Plast Surg*. 2018;81(4):487-94.
- Kim YH, Lee HE, Lee JH, Kim JT, Kim SW. Reliability of eccentric position of the pedicle instead of central position in a thoracodorsal artery perforator flap. *Microsurgery*. 2017;37(1):44-8.
- Reddy T, Dikshit V, Tilak B, Ganesh M. Thoracodorsal artery perforator flap in immediate breast reconstruction: A series of twenty cases. *Int Surg J*. 2019;7(1):205-9.
- Heitmann C, Guerra A, Metzinger SW, Levin LS, Allen RJ. The thoracodorsal artery perforator flap: Anatomic basis and clinical application. *Ann Plast Surg*. 2003;51(1):23-9.
- Roy M, Shrotria S, Holcombe C, Webster D, Hughes L, Mansel R. Complications of latissimus dorsi myocutaneous flap breast reconstruction. *Eur J Surg Oncol*. 1998;24(3):162-5.
- Ho A, Cordeiro P, Disa J, Mehrara B, Wright J, Van Zee KJ, et al. Long-term outcomes in breast cancer patients undergoing immediate 2-stage expander/implant reconstruction and postmastectomy radiation. *Cancer*. 2012;118(9):2552-9.

20. Tarantino I, Banic A, Fischer T. Evaluation of late results in breast reconstruction by latissimus dorsi flap and prosthesis implantation. *Plast Reconstr Surg.* 2006;117(5):1387-94.
21. Ortiz CL, Mendoza MM, Sempere LN, Sanz JS, Torres AN, Barraquer EL. Versatility of the pedicled Thoracodorsal Artery Perforator (TDAP) flap in soft tissue reconstruction. *Ann Plast Surg.* 2007;58(3):315-20.
22. Hamdi M, De Frene B, editors. Pedicled perforator flaps in breast reconstruction. *Semin Plast Surg.* 2006;20(2):73-8.
23. Hamdi M, Van Landuyt K, Van Hedent E, Duyck P. Advances in autogenous breast reconstruction: The role of preoperative perforator mapping. *Ann Plast surg.* 2007;58(1):18-26.
24. Kim JG, Lee SH. Comparison of the multidetector-row computed tomographic angiography axial and coronal planes' usefulness for detecting thoracodorsal artery perforators. *Arch Plast Surg.* 2012;39(4):354.